



LUNG ULTRASOUND AS AN ASSESSMENT TOOL IN ICU FOR CRITICALLY ILL PATIENTS AT A TERTIARY CARE CENTER IN SRINAGAR: A PROSPECTIVE OBSERVATIONAL STUDY

Dr. Syed Nazima, Dr. Rayees Najib^{2*}, Prof. Hina Bashir Shah³, Dr. Mudasir Qurpal⁴

¹Assistant Professor, Department of Anesthesia Critical Care Pain and Palliative Medicine, Government Medical College Srinagar, Jammu and Kashmir, India.

^{2*}Assistant Professor, Department of Anesthesia Critical Care Pain and Palliative Medicine, Government Medical College Srinagar, Jammu and Kashmir, India.

³Professor and Head, Department of Anesthesia Critical Care Pain and Palliative Medicine, Government Medical College Srinagar, Jammu and Kashmir, India.

⁴Senior Resident, Department of Anesthesia Critical Care Pain and Palliative Medicine, Government Medical College Srinagar, Jammu and Kashmir, India.

Corresponding Author: Dr. Rayees Najib

Assistant Professor, Department of Anesthesia Critical Care Pain and Palliative Medicine, Government Medical College Srinagar, Jammu and Kashmir, India.

ABSTRACT

Background: Lung ultrasound (LUS) has emerged as a rapid, bedside, non-invasive imaging modality for the evaluation of pulmonary pathologies in critically ill patients. Its increasing use in intensive care units (ICUs) is driven by its high diagnostic accuracy, repeatability, and real-time applicability. **Objectives:** To assess the utility of lung ultrasound in identifying and differentiating various pulmonary pathologies in critically ill ICU patients and to evaluate the association between sonographic findings and final clinical diagnoses. **Methods:** This prospective observational study included 50 adult patients (>18 years) admitted to the ICU of a tertiary care center. Lung ultrasound was performed using a standardized zonal scanning protocol. Sonographic findings were correlated with clinical diagnoses. Statistical analysis was performed using SPSS version 23. Categorical variables were expressed as frequencies and percentages, and associations were analyzed using the Chi-square test, with a p-value <0.05 considered statistically significant. **Results:** The majority of patients were in the 60–69 years age group (32%), with a male predominance (58%). Common comorbidities included multiple comorbid conditions (26%), hypertension (20%), and chronic obstructive pulmonary disease (14%). On lung ultrasound, B-lines were observed in 18% of patients, A-lines in 10%, lung sliding in 8%, and the barcode sign in 10%. The most common diagnoses were lung consolidation (34%), followed by pleural effusion (24%), pulmonary edema (18%), acute respiratory distress syndrome (14%), and pneumothorax (10%). A highly significant association was observed between B-lines and pulmonary edema (100% vs 0%, $p < 0.001$). A-lines showed a strong association with pneumothorax (80% vs 6.7%, $p < 0.001$) and were absent in cases of consolidation ($p < 0.01$). No significant association was found between pleural effusion and pneumothorax ($p = 0.785$). **Conclusion:** Lung ultrasound is a reliable and effective bedside diagnostic tool for evaluating pulmonary pathologies in critically ill patients. Specific sonographic patterns, particularly B-lines and A-lines, demonstrate strong correlations with pulmonary edema and pneumothorax, respectively, underscoring the diagnostic accuracy and clinical utility of LUS in ICU settings.

Keywords: Lung Ultrasound, Intensive Care Unit, B-Lines, A-Lines, Pneumothorax, Pleural Effusion, Pulmonary Edema, ARDS, Point-Of-Care Ultrasound (POCUS).

INTRODUCTION

Imaging plays an indispensable role in the assessment and ongoing management of critically ill patients in the intensive care unit (ICU). Alongside clinical examination and laboratory parameters, imaging facilitates accurate diagnosis, guides therapeutic interventions, and enables monitoring of disease progression or resolution.

Traditionally, portable chest radiography and computed tomography (CT) have served as the cornerstone of thoracic imaging in critically ill patients. However, CT imaging is often limited by the need to transport hemodynamically unstable patients, while chest radiography frequently produces suboptimal or inconclusive results due to supine positioning, technical limitations, and overlapping pulmonary pathologies^{1,2}.

In contrast, the advent of bedside ultrasonography has led to a paradigm shift in ICU imaging³. Lung ultrasound (LUS) has emerged as a rapid, real-time, non-invasive diagnostic modality capable of



www.ajmrhs.com
eISSN: 2583-7761

Date of Received: 02-04-2026
Date Acceptance: 10-04-2026
Date of Publication: 06-05-2026

evaluating lung parenchyma, pleural space, and diaphragm without exposure to ionizing radiation. It is safe, repeatable, and easily performed at the bedside, making it particularly suitable for critically ill patients requiring continuous monitoring^{4,5}.

LUS provides valuable diagnostic information through the interpretation of characteristic sonographic artifacts and patterns⁶⁻⁸. Normal lung ultrasound findings include lung sliding, horizontal reverberation artifacts known as A-lines, and vertical comet-tail artifacts known as B-lines. A-lines indicate normally aerated lung, whereas B-lines reflect increased extravascular lung water and interstitial involvement⁹⁻¹¹. The pleural line appears as a hyperechoic structure just beneath the rib line, and its movement during respiration corresponds to lung sliding. In M-mode imaging, normal lung produces the characteristic “seashore sign,” representing normal pleural motion^{12,13}.

One of the key strengths of LUS is its ability to differentiate pulmonary conditions based on their acoustic signatures. Conventional chest radiography often fails to reliably distinguish between consolidation, pleural effusion, and pulmonary edema, whereas lung ultrasound allows accurate bedside differentiation¹⁴⁻¹⁸. Pleural effusions typically appear as anechoic or hypoechoic collections, consolidations demonstrate a tissue-like echotexture with dynamic air bronchograms, and interstitial syndromes present with multiple diffuse B-lines¹⁹⁻²².

Pneumothorax, an important and potentially life-threatening condition in critically ill patients, can also be reliably diagnosed using LUS. It is characterized by the absence of lung sliding and B-lines and may demonstrate the “stratosphere” or “barcode” sign on M-mode imaging²³⁻²⁶. The identification of the lung point, representing the transition between normal lung and pneumothorax, is highly specific and can also provide an estimate of pneumothorax size²⁷⁻³².

Given its diagnostic accuracy, rapid applicability, and safety profile, lung ultrasound has become an essential component of point-of-care ultrasound (POCUS) in modern critical care practice. The present study was undertaken to evaluate the utility of lung ultrasound in detecting and differentiating pulmonary pathologies in critically ill ICU patients and to assess the association between sonographic findings and final clinical diagnoses.

Aims and Objectives

To Study the utility of bedside lung ultrasound in assessing the various lung pathologies in patients admitted in ICU.

Monitoring pleural effusions, detecting pneumothorax, consolidation and assessing lung parenchyma and providing rapid bedside assessment to aid in patient management.

MATERIALS AND METHODS

Study design and setting

This prospective observational study was conducted in the Department of Anaesthesiology, Critical Care and Pain Management at Government Medical College Srinagar and its associated hospitals after obtaining approval from the Institutional Ethics Committee. The study was carried out over a period of 18 months, from September 2023 to February 2025.

Study population

A total of 50 critically ill patients admitted to the intensive care unit (ICU) were enrolled consecutively after fulfilling the inclusion criteria. Written informed consent was obtained from the patients or their legally authorized representatives.

Inclusion criteria

- Adult patients aged ≥ 18 years
- Patients with respiratory compromise, defined as oxygen saturation (SpO₂) <90% on room air or arterial oxygen tension (PaO₂) <60 mmHg on arterial blood gas analysis

Exclusion criteria

- Age <18 years
- Patients in whom lung ultrasound examination was not feasible

Clinical evaluation

All enrolled patients underwent detailed clinical assessment, including history, physical examination, and relevant laboratory investigations as per standard ICU protocols.

Lung ultrasound technique

Lung ultrasound (LUS) was performed at the bedside using a portable ultrasound machine by an experienced operator. Both high-frequency linear probes (5–12 MHz) and low-frequency curvilinear (3–5 MHz) probes were utilized depending on the region of interest and required depth of penetration. Ultrasound examination was systematically performed over both hemithoraces using a standardized six-zone scanning protocol for each lung. Each hemithorax was divided into anterior, lateral, and posterior regions, further subdivided into upper and lower zones using anatomical landmarks including the anterior and posterior axillary lines.

Most patients were examined in the supine position; however, lateral positioning was used when feasible to allow better visualization of posterior lung fields.

Ultrasound findings and diagnostic criteria

Each lung zone was assessed for characteristic sonographic findings, including A-lines, B-lines, lung sliding, pleural effusion, and lung consolidation. M-mode ultrasonography was used to evaluate dynamic signs such as lung sliding and to identify patterns such as the seashore sign and barcode sign, particularly in suspected pneumothorax. Colour Doppler imaging was used selectively to differentiate vascular from avascular structures and to assess pleural dynamics.

Based on lung ultrasound findings, patients were categorized into the following diagnostic groups:

- Lung consolidation
- Pleural effusion
- Pulmonary edema
- Acute respiratory distress syndrome (ARDS)
- Pneumothorax

Outcome Measures

The primary outcome was the diagnostic utility of lung ultrasound in identifying and differentiating pulmonary pathologies in critically ill patients. Secondary outcomes included the association between specific ultrasound findings and final clinical diagnoses.

Statistical Analysis

Data were entered into Microsoft Excel and analyzed using Statistical Package for the Social Sciences (SPSS) version 23 (SPSS Inc., Chicago, USA). Categorical variables were expressed as frequencies and percentages, while continuous variables were presented as mean ± standard deviation.

Associations between categorical variables were analyzed using the Chi-square test or Fisher’s exact

test, as appropriate. A p-value <0.05 was considered statistically significant.

RESULTS

A total of 50 critically ill patients admitted to the intensive care unit (ICU) were included in the study. Lung ultrasound findings were analyzed with respect to demographic profile, comorbid illnesses, procedural characteristics, sonographic findings, final diagnoses, and their statistical associations.

Baseline demographic and clinical characteristics

The majority of patients belonged to the 60–69 years age group (32%), followed by 40–49 years (20%) and 30–39 years (18%). The mean distribution showed a predominance of elderly patients. Males constituted 58% of the study population, while females accounted for 42%.

Multiple comorbidities were the most common clinical finding (26%), followed by hypertension (20%) and chronic obstructive pulmonary disease (14%). Other comorbid conditions included diabetes mellitus, chronic kidney disease, and combined disease states (Table 1).

Table 1. Baseline Demographic and Clinical Characteristics of the Study Population

Variable	Category	Frequency (n)	Percentage (%)
Age group (years)	18–29	5	10.0
	30–39	9	18.0
	40–49	10	20.0
	50–59	4	8.0
	60–69	16	32.0
	70–79	4	8.0
	80–90	2	4.0
Gender	Male	29	58.0
	Female	21	42.0
Comorbidity	Multiple comorbidities	13	26.0
	Hypertension (HTN)	10	20.0
	COPD	7	14.0
	No comorbidity	6	12.0
	Diabetes mellitus (DM)	5	10.0
	Chronic kidney disease (CKD)	4	8.0
	HTN + DM	3	6.0
	DM + COPD	2	4.0

Procedural characteristics of lung ultrasound

Lung ultrasound was most commonly performed in the lateral position (40%), followed by a combination of supine and lateral positioning (32%), and supine position alone (28%). The linear probe

was used in 40% of cases, while convex probes were used in 32%. In 28% of patients, both probes were utilized depending on the depth and nature of pathology (Table 2).

Table 2. Procedural Characteristics of Lung Ultrasound Examination

Variable	Category	Frequency (n)	Percentage (%)
Position during LUS	Lateral	20	40.0
	Supine + lateral	16	32.0
	Supine	14	28.0
Probe used	Linear	20	40.0
	Convex	16	32.0

	Both	14	28.0
--	------	----	------

Sonographic Findings

Among lung ultrasound findings, B-lines were observed in 18% of patients, while A-lines were present in 10%. Lung sliding was absent in the

majority of patients. The barcode sign, suggestive of pneumothorax, was identified in 10% of cases (Figure 1).

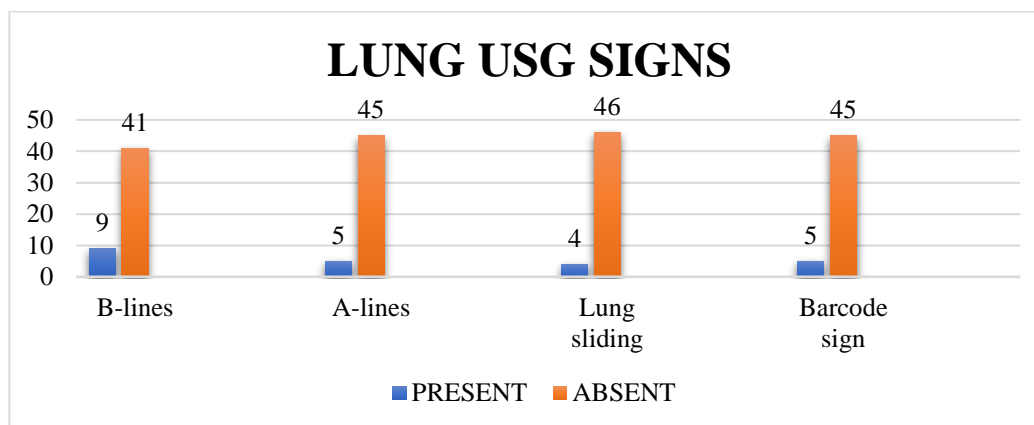


Figure 1. Distribution of Key Lung Ultrasound Signs

Final lung ultrasound diagnosis

The most common diagnosis on lung ultrasound was lung consolidation (34%), followed by pleural effusion (24%), pulmonary edema (18%), and acute

respiratory distress syndrome (ARDS) (14%). Pneumothorax was the least common finding, observed in 10% of patients (Figure 2).

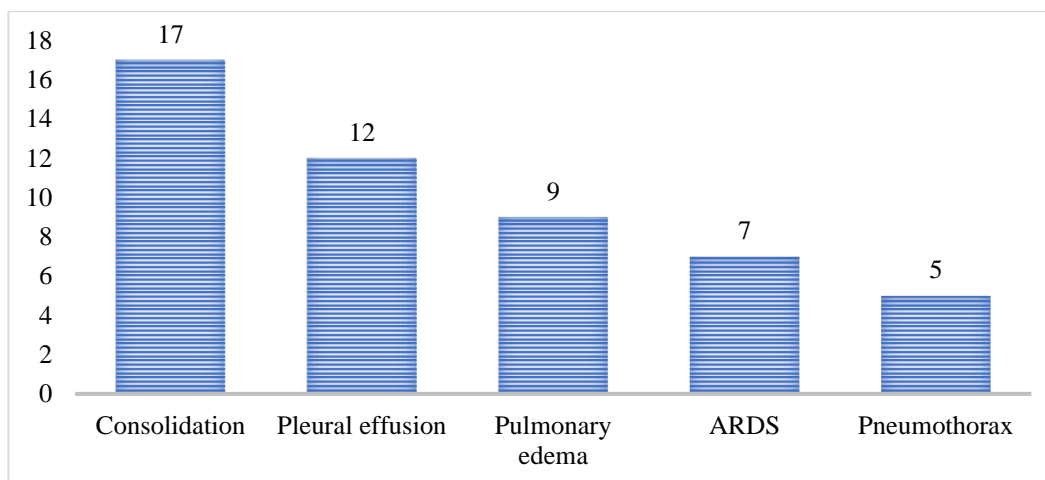


Figure 2. Final Lung Ultrasound Diagnosis

Correlation between pleural effusion and pneumothorax

Among patients without pleural effusion, pneumothorax was present in 3 cases, whereas 2 cases of pneumothorax were noted among patients

with pleural effusion. However, this association was not statistically significant ($p = 0.785$), indicating that pleural effusion and pneumothorax occurred independently in this cohort (Table 3).

Table 3. Correlation between Pleural Effusion and Pneumothorax

Pleural effusion	Pneumothorax absent	Pneumothorax present	Total
Absent	35	3	38
Present	10	2	12
Total	45	5	50

Correlation between pulmonary edema and B-lines

A highly significant association was observed between pulmonary edema and B-lines. All patients

with pulmonary edema demonstrated B-lines, while none of the patients without pulmonary edema showed B-lines ($p < 0.001$) (Table 4).

Table 4. Correlation between Pulmonary Edema and B-Lines

Pulmonary edema	B-lines present	B-lines absent	Total
Present	9	0	9
Absent	0	41	41
Total	9	41	50

Correlation between pneumothorax and A-lines

A statistically significant association was found between pneumothorax and A-lines. A-lines were

present in the majority of patients with pneumothorax and were infrequent in patients without pneumothorax ($p < 0.001$) (Table 5).

Table 5. Correlation between pneumothorax and A-lines

Pneumothorax	A-lines absent	A-lines present	Total
Absent	42	3	45
Present	1	4	5
Total	43	7	50

Correlation between consolidation and A-lines

An inverse relationship was observed between consolidation and A-lines. None of the patients with

consolidation demonstrated A-lines, whereas A-lines were present only in patients without consolidation ($p < 0.01$) (Table 6).

Table 6. Correlation between consolidation and A-lines

Consolidation	A-lines absent	A-lines present	Total
Absent	26	17	43
Present	7	0	7
Total	33	17	50

Summary of key findings

In this study, lung ultrasound identified consolidation as the most common pulmonary pathology in critically ill patients, followed by pleural effusion, pulmonary edema, ARDS, and pneumothorax. The study population predominantly comprised elderly males with multiple comorbidities.

Among sonographic signs, B-lines showed a strong association with pulmonary edema, while A-lines were significantly associated with pneumothorax and were absent in consolidation. No significant association was observed between pleural effusion and pneumothorax.

DISCUSSION

Lung ultrasound (LUS) has increasingly established itself as an indispensable bedside imaging modality in the intensive care unit (ICU), owing to its rapidity, non-invasive nature, and ability to provide real-time dynamic assessment. In the present study, its role in evaluating critically ill patients across a spectrum of thoracic pathologies was explored, and the findings strongly reinforce its growing clinical relevance. As emphasized by Mojoli et al.²³, LUS not only facilitates immediate diagnosis but also enables continuous monitoring of lung pathology, making it particularly well suited for the ICU environment.

The demographic profile of the study population revealed a predominance of elderly patients, particularly those in the sixth and seventh decades of life. This observation reflects the well-recognized vulnerability of this age group to respiratory compromise and critical illness. Similar trends have been reported by Lichtenstein et al.¹⁸, Mongodi et al.²⁸, and Xirouchaki et al.²⁶, who highlighted the increased burden of ICU admissions among older individuals due to declining physiological reserves and a higher prevalence of comorbidities.

A male predominance was observed in the present study, consistent with previously reported data. Studies by Xirouchaki et al.¹⁹ and Ali et al.²⁰, along with larger analyses by Yuan et al.²² and Lau and See²², suggest that males are more frequently represented in ICU settings, possibly due to greater exposure to risk factors and increased disease severity.

The burden of comorbid conditions such as hypertension, chronic obstructive pulmonary disease, diabetes mellitus, and chronic kidney disease further highlights the complex clinical profile of critically ill patients. These findings are in agreement with those of Breitkopf et al.²⁹ and Chavez et al.³⁰, who demonstrated that underlying systemic illnesses significantly influence ICU

admission patterns as well as lung ultrasound findings.

From a technical standpoint, the flexibility in patient positioning—utilizing supine, lateral, or combined approaches—enhanced diagnostic yield in the present study. This is in line with recommendations by Lichtenstein and Mezière²¹, who advocated comprehensive thoracic scanning to improve detection of posterior lung pathologies. Similarly, Volpicelli et al.¹⁶ and Mongodi et al.²⁸ emphasized that combining different patient positions increases the sensitivity of LUS, particularly in mechanically ventilated patients.

Probe selection in this study reflected a pragmatic and clinically adaptive approach. Linear probes were useful for assessing pleural abnormalities and lung sliding, as noted by Xirouchaki et al.²⁶, whereas convex probes allowed better visualization of deeper lung structures, consistent with findings by Volpicelli et al.¹⁶. The complementary use of both probes, as described by Lichtenstein et al.²⁴, enhances overall diagnostic accuracy.

Analysis of ultrasound artifacts revealed that B-lines were the most frequently observed finding, reflecting their strong association with interstitial syndromes such as pulmonary edema and ARDS. This observation is supported by Lichtenstein et al.²⁴ and Volpicelli et al.¹⁶, with further corroboration from Breikopf et al.²⁹. In contrast, A-lines were associated with normal lung aeration or pneumothorax, as described by Mongodi et al.²⁸ and Xirouchaki et al.²⁶. The presence or absence of lung sliding remains a critical diagnostic parameter, with Lichtenstein and Mezière²¹ demonstrating its high negative predictive value for pneumothorax.

The role of M-mode ultrasound was particularly evident in the identification of the barcode (stratosphere) sign in cases of pneumothorax. This finding is consistent with earlier work by Lichtenstein and Mezière²¹ and Volpicelli et al.¹⁶, who highlighted its diagnostic specificity. Similar observations by Xirouchaki et al.¹⁹ and Soldati et al.³¹ further reinforce its clinical utility.

Among the various pathologies identified, lung consolidation emerged as the most common diagnosis, followed by pleural effusion, pulmonary edema, ARDS, and pneumothorax. This pattern aligns with findings reported by Lichtenstein and Mezière²¹ and Mongodi et al.²⁸, emphasizing the predominance of alveolar and interstitial pathologies in critically ill patients. The relatively lower incidence of pleural effusion compared to studies by Volpicelli et al.¹⁶ and Xirouchaki et al.¹⁹ may be attributable to differences in patient characteristics and timing of evaluation.

A particularly significant finding in the present study was the strong association between B-lines and pulmonary edema, with all patients diagnosed with pulmonary edema demonstrating B-lines. This

is consistent with previous studies by Lichtenstein and Mezière²¹, Volpicelli et al.¹⁶, and El Gendy et al.²⁷, which established B-lines as reliable indicators of interstitial fluid accumulation.

Similarly, A-lines showed a significant association with pneumothorax, particularly when interpreted alongside absent lung sliding. This relationship has been well described by Lichtenstein and Mezière²¹ and Volpicelli et al.¹⁶. Furthermore, the absence of A-lines in patients with lung consolidation observed in this study reinforces the established concept that A-lines are characteristic of normally aerated lung tissue. This inverse relationship has been consistently reported by Lichtenstein and Mezière²¹, Volpicelli et al.¹⁶, and Xirouchaki et al.²⁶.

In summary, the findings of the present study underscore the robustness, versatility, and diagnostic accuracy of lung ultrasound as a bedside tool in critically ill patients. Its strong correlation with established literature, combined with its ability to provide rapid, repeatable, and radiation-free assessment, highlights its indispensable role in modern intensive care practice.

CONCLUSION

The present study demonstrates that lung ultrasound (LUS) is a reliable, rapid, and non-invasive bedside imaging modality for the evaluation of pulmonary pathologies in critically ill patients. LUS effectively identified a spectrum of conditions in the ICU setting, with lung consolidation being the most common diagnosis, followed by pleural effusion, pulmonary edema, ARDS, and pneumothorax.

Specific sonographic signs showed strong diagnostic associations. B-lines demonstrated a significant correlation with pulmonary edema, while A-lines were significantly associated with pneumothorax and were absent in cases of lung consolidation, highlighting their diagnostic value in differentiating pulmonary pathologies. No significant association was observed between pleural effusion and pneumothorax.

Overall, lung ultrasound provides accurate, real-time assessment at the bedside and has significant potential to aid early diagnosis, guide management, and monitor disease progression in critically ill patients. Its ease of use and applicability make it a valuable adjunct in routine ICU practice.

Limitations

The present study has certain limitations. First, the sample size was relatively small and derived from a single tertiary care center, which may limit the generalizability of the findings. Second, lung ultrasound examinations were performed by an experienced operator, and inter-observer variability was not assessed, which may influence reproducibility in different clinical settings. Third, correlation with gold-standard imaging modalities such as computed tomography was not performed in

all patients, which may limit definitive validation of ultrasound findings.

Additionally, the study population consisted of critically ill ICU patients with heterogeneous underlying conditions, which may have influenced the distribution of sonographic findings. Finally, the cross-sectional design limits the ability to assess longitudinal changes and the role of lung ultrasound in monitoring disease progression over time.

Conflict of interest: Nil

Funding: Nil

REFERENCES

1. Porte F, Basit R, Howlett D. Imaging in the intensive care unit. *Crit Illness Intensive Care* 2009;27:496–9.
2. Moghekar A, Mehta A. Thoracic ultrasound: a picture worth a thousand sounds. *Ann Thorac Med* 2014;9:185.
3. Demi L, Demi M, Smargiassi A, Inchingolo R, Fata F, Soldati G, et al. Ultrasonography in lung pathologies: new perspectives. *Multidisc Respir Med* 2014;9:27.
4. Bouhemad B, Zhang M, Lu Q, Rouby JJ. Clinical review: bedside lung ultrasound in critical care practice. *Crit Care* 2007;11:205.
5. Refaat R, Abdurrahman LA. The diagnostic performance of chest ultrasonography in the up-to-date work-up of the critical care setting. *Egypt J Radiol Nucl Med* 2013;779–89.
6. Winkler MH, Touw HR, van de Ven PM, Twisk J, Tuinman PR. Diagnostic accuracy of chest radiograph, and when concomitantly studied lung ultrasound, in critically ill patients with respiratory symptoms: a systematic review and meta-analysis. *Crit Care Med*. 2018; 46: e707–e714.
7. Soummer A, Perbet S, Brisson H, Arbelot C, Constantin JM, Lu Q, Rouby JJ. Ultrasound assessment of lung aeration loss during a successful weaning trial predicts postextubation distress. *Crit Care Med*. 2012; 40:2064–72.
8. Li L, Yang Q, Li L, Guan J, Liu Z, Han J, Chao Y, Wang Z, Yu X. The value of lung ultrasound score on evaluating clinical severity and prognosis in patients with acute respiratory distress syndrome. *Zhonghua Wei Zhong Bing Ji Jiu Yi Xue* 2015;27:579–84.
9. Haddam M, Zieleskiewicz L, Perbet S, Baldovini A, Guervilly C, Arbelot C, Noel A, Vigne C, Hammad E, Antonini F et al. Lung ultrasonography for assessment of oxygenation response to prone position ventilation in ARDS. *Intensive Care Med*. 2016;42:1546–56.
10. Caltabelotti FP, Monsel A, Arbelot C, Brisson H, Lu Q, Gu W J et al. Early fluid loading in acute respiratory distress syndrome with septic shock deteriorates lung aeration without impairing arterial oxygenation: a lung ultrasound observational study. *Crit Care* 2014;18:R91.
11. Bouhemad B, Brisson H, Le-Guen M, Arbelot C, Lu Q, Rouby JJ. Bedside ultrasound assessment of positive end-expiratory pressure-induced lung recruitment. *Am J Respir Crit Care Med*. 2011;183:341–47.
12. Greenbaum DM, Marschall KE. The value of routine daily chest X-rays in intubated patients in the medical intensive care unit. *Crit Care Med* 1982;10: 29–30.
13. Via G, Storti E, Gulati G, Neri L, Mojoli F, Braschi A. Lung ultrasound in the ICU: from diagnostic instrument to respiratory monitoring tool. *Minerva Anestesiol* 2012; 78: 1282–96.
14. Baldi G, Gargani L, Abramo A, D'Errico L, Caramezza D, Picano E, et al: Lung water assessment by lung ultrasonography in intensive care: a pilot study. *Intensive Care Med* 2013; 39: 74–84.
15. Via G, Lichtenstein D, Mojoli F, Rodi G, Neri L, Storti E, et al: Whole lung lavage: a unique model for ultrasound assessment of lung aeration changes. *Intensive Care Med* 2010; 36: 999–1007.
16. Volpicelli G, Elbarbary M, Blaivas M, Lichtenstein DA, Mathis G, Kirkpatrick AW, et al. International evidence-based recommendations for point-of-care lung ultrasound. *Intensive Care Med*. 2012;38:577–91.
17. Soummer A, Perbet S, Brisson H, Arbelot C, Constantin JM, Lu Q, Rouby JJ. Ultrasound assessment of lung aeration loss during a successful weaning trial predicts postextubation distress. *Crit Care Med*. 2012;40:2064–72.
18. Lichtenstein D, Mezière G, Seitz J. The dynamic air bronchogram. A lung ultrasound sign of alveolar consolidation ruling out atelectasis. *Chest*. 2009;135:1421–5.
19. Xirouchaki N, Magkanas E, Vaporidi K, Kondili E, Plataki M, Patrianakos A, et al. Lung ultrasound in critically ill patients: comparison with bedside chest radiography. *Intensive Care Med*. 2011;37(9):1488–93.
20. Ali NM, Maguid H, Gamil NM, Tawfeek MM, Hegab SS. Evaluation of the role of bedside lung ultrasound versus chest x-ray in critically ill patients. *Zagazig Univ Med J*. 2019;25(6):887–97.
21. Lichtenstein DA, Mezière GA. Relevance of lung ultrasound in the diagnosis of acute respiratory failure: the BLUE protocol. *Chest*. 2008;134(1):117–25.

22. Lau YH, See KC. Point-of-care ultrasound for critically ill patients: A mini-review of key diagnostic features and protocols. *World J Crit Care Med.* 2022;11(2):70–84.
23. Mojoli F, Bouhemad B, Mongodi S, Lichtenstein D. Lung ultrasound for critically ill patients. *Am J Respir Crit Care Med.* 2019;199(6):701–14.
24. Lichtenstein DA, Mezière GA, Lagoueyte JF, Biderman P, Goldstein I, Gepner A. A-lines and B-lines: lung ultrasound as a bedside tool for predicting pulmonary artery occlusion pressure in the critically ill. *Chest.* 2009;136(4):1014–20.
25. Yuan X, Liu L, Chang W, Wu Z, Huang L, Chao Y, et al. Diagnostic accuracy of lung ultrasound for ARF in critically ill patients: a systematic review and meta-analysis. *Front Med.* 2021;8:705960.
26. Xirouchaki N, Kondili E, Prinianakis G, Malliotakis P, Georgopoulos D. Impact of lung ultrasound on clinical decision making in critically ill patients. *Intensive Care Med.* 2014;40(1):57–65.
27. El Gendy M, Abdalla W, Abdelaziz AA, Ammar MA. Lung ultrasound versus chest radiography for the diagnosis of pneumothorax in critically ill patients: A prospective, single-blind study. *Saudi J Anaesth.* 2018;265–69.
28. Mongodi S, Orlando A, Arisi E, Tavazzi G, Santangelo E, Caneva L, et al. Lung ultrasound in patients with acute respiratory failure reduces conventional imaging and healthcare provider exposure to COVID-19. *Ultrasound Med Biol.* 2020;46:2090–93.
29. Breitkopf R, Treml B, Rajsic S. Lung sonography in critical care medicine. *Diagnostics (Basel).* 2022;12(6):1405.
30. Chavez MA, Shams N, Ellington LE, Naithani N, Gilman RH, Steinhoff MC, et al. Lung ultrasound for the diagnosis of pneumonia in adults: a systematic review and meta-analysis. *Respir Res.* 2014;15(1):50.
31. Soldati G, Testa A, Sher S, Pignataro G, La Sala M, Silveri NG. Occult traumatic pneumothorax: diagnostic accuracy of lung ultrasonography in the emergency department. *Chest.* 2008;133(1):204–11.

How to cite this article Dr. Syed Nazima, Dr. Rayees Najib, Prof. Hina Bashir Shah, Dr. Mudasir Qurpal, LUNG ULTRASOUND AS AN ASSESSMENT TOOL IN ICU FOR CRITICALLY ILL PATIENTS AT A TERTIARY CARE CENTER IN SRINAGAR: A PROSPECTIVE OBSERVATIONAL STUDY, *Asian J. Med. Res. Health Sci.*, 2026; 4 (1):-38-45.

Source of Support: Nil, Conflicts of Interest: None declared.