



OUTCOME OF LARGE MENINGIOMA SURGERIES WITH PREOPERATIVE DIGITAL SUBTRACTION ANGIOGRAPHY (DSA): A CLINICAL STUDY

Dr. Angirash Bhattacharyya^{1*}, Dr. Ashim Kumar Boro², Prof (Dr) Mrinal Bhuyan³, Dr. Rajesh Kr. Barooah⁴

¹Consultant Neurosurgeon, Nemcare Hospitals, Guwahati and Tezpur, Assam, India.

²Assistant Professor, Dept. of Neurosurgery, CN Center, Gauhati Medical College & Hospital, Guwahati, Assam, India.

³Professor & HOD, Dept. of Neurosurgery, CN Center, Gauhati Medical College & Hospital, Guwahati, Assam, India.

⁴Professor, Dept. of Neurosurgery, Assam Medical College & Hospital, Guwahati, Assam, India.

Corresponding Author: Dr. Angirash Bhattacharyya

Consultant Neurosurgeon, Nemcare Hospitals, Guwahati and Tezpur, Assam, India.

ABSTRACT

Background: The management of large meningiomas presents unique challenges due to their size, vascularity, and potential proximity to critical neurovascular structures. Preoperative Digital Subtraction Angiography (DSA) is a diagnostic tool that can aid in surgical planning by providing detailed vascular maps of these tumors. This study investigates the outcomes of large meningioma surgeries managed with preoperative DSA.

Methods: This prospective study included 15 patients with large intracranial meningiomas, of which 8 underwent preoperative embolization (embolization grp), and 7 did not (non-embolization grp). The outcomes assessed included the extent of tumor resection, operative time, intraoperative blood loss, and postoperative complications. Multivariate analyses were performed to identify factors associated with favourable outcomes.

Results: Preoperative DSA provided valuable information that guided surgical strategy, particularly in achieving complete tumor resection. The overall rate of complete resection (Simpson grade I-II) was high, with 80% of patients achieving this outcome. The average operative time was 265.7 ± 70.3 minutes, and the mean intraoperative blood loss was 500.7 ± 200.4 mL. Postoperative complications were relatively low, with a complication rate of 30%.

Conclusion: Preoperative DSA plays a crucial role in the management of large meningiomas by enhancing surgical planning and potentially improving surgical outcomes. The use of DSA allows for better visualization of the tumor's vascular supply, aiding in the safe and effective resection of these challenging tumors.

Keywords: Intracranial, Meningioma, Preoperative, Angiography, Embolization.

INTRODUCTION

Meningiomas are the prevalent primary intracranial tumors, representing around 30% of all primary brain tumors [1]. They stem from the meningotheelial cells of the arachnoid layer and are generally considered benign, slow-growing tumors [2]. However, meningiomas can cause significant morbidity and mortality depending on their location, size, and proximity to critical neurovascular structures [3].

Surgical resection continues to be the primary treatment for symptomatic or growing meningiomas [4]. The objective of surgical procedure is to remove the entire tumor whilst reducing neurological deficits.

However, complete resection can be challenging, especially for large, vascular, or skull base meningiomas [5]. In such cases, preoperative embolization has been proposed to reduce tumor vascularity, minimize intraoperative blood loss, and facilitate complete resection [6].

Preoperative embolization involves the targeted catheterization and blockage of the arteries that supply blood to the meningioma, typically performed 24-48 hours before surgical resection [7]. The rationale behind this approach is that reducing tumor vascularity can lead to a more bloodless surgical field, shorter operative time, and lower risk of complications [8]. However, the efficacy and safety of preoperative embolization for meningiomas remain controversial, with conflicting results reported in the literature [9].

Some studies have demonstrated the benefits of preoperative embolization, such as reduced loss of intraoperative blood, shorter operative time, and higher rates of complete resection [6, 8]. A study by



www.ajmrhs.com
eISSN: 2583-7761

Date of Received: 13-04-2026
Date Acceptance: 19-04-2026
Date of Publication: 20-05-2026

Raper et al. observed that preoperative embolization was linked with notably lower intraoperative blood loss and a lower need for transfusions compared to cases without embolization [6]. Similarly, a systematic review by Shah et al. concluded that preoperative embolization could be a valuable adjunct to surgery, particularly for large, vascular, or skull base meningiomas [8].

On the other hand, other studies have questioned the routine use of preoperative embolization, citing potential risks and complications, such as intratumoral hemorrhage, cerebral ischemia, and cranial nerve palsies [9,10]. A retrospective study by Carli et al. observed no significant difference in the extent of resection, operative time, or complication rates between embolized and non-embolized cases [9]. Furthermore, a meta-analysis determined that the current evidence was not enough to support the regular use of preoperative embolization for meningiomas [10].

Given the conflicting evidence and lack of consensus, there is a need for further prospective studies to evaluate the surgical outcomes of meningiomas with and without preoperative embolization. This prospective study aims to compare the extent of resection, operative time, intraoperative blood loss, and complications between embolized and non-embolized cases of meningiomas. The observations of this study could offer essential information of the role of preoperative embolization in managing meningiomas and help inform clinical decision-making.

Aims & Objectives

The study aims to evaluate the surgical outcomes of large meningiomas managed with preoperative DSA, focusing on the extent of resection, operative time, intraoperative blood loss, and postoperative complications.

Materials & Methods

Study Design & Study Setting:

The observational study was carried out in a tertiary care neurosurgical center between January 1, 2023, and June 15, 2024. The institutional ethics committee allowed the study protocol, and all participants gave informed consent.

Patient Selection

Fifteen patients with radiologically confirmed intracranial meningiomas scheduled for surgical resection during the study period were recruited. The inclusion criteria were: (1) age ≥ 18 years, (2) Karnofsky Performance Scale (KPS) score ≥ 70 , (3) no previous history of meningioma surgery or radiotherapy, and (4) no contraindications to angiography or embolization. The exclusion criteria were Patients with (1) multiple meningiomas, (2) en-plaque or optic sheath meningiomas, (3) severe comorbidities, or (4) pregnancy.

Preoperative Evaluation

All patients underwent a detailed preoperative assessment, including clinical assessment, neurological examination, and imaging studies (contrast-enhanced MRI and CT angiography). The tumor size, location, and vascularity were assessed by a neuroradiologist blinded to the treatment Grp. Based on the tumor characteristics and patient factors, the decision to perform preoperative embolization was made by a multidisciplinary team consisting of neurosurgeons, interventional neuroradiologists, and anesthesiologists.

Preoperative Embolization

Patients in the embolization Grp underwent targeted catheterization and occlusion of the feeding arteries supplying the meningioma, performed by experienced interventional neuroradiologists. The embolization procedure was typically performed 24-48 hours before the scheduled surgical resection. The embolic agents used were polyvinyl alcohol particles (150-250 μm) or tris-acryl gelatin microspheres (100-300 μm), depending on the operator's preference and the vascular anatomy. The extent of embolization was assessed by post-embolization angiography and graded as complete ($>90\%$ reduction in tumor blush), partial (50-90% reduction), or incomplete ($<50\%$ reduction).

Surgical Procedure

All patients underwent craniotomy and tumor resection under general anesthesia, performed by experienced neurosurgeons. The extent of resection was evaluated during the surgery and verified by a postoperative contrast-enhanced MRI within 48 hrs after the operation. The range of resection was categorized using the Simpson classification: grade I (total removal including abnormal bone and dural attachment), grade II (total removal with coagulation of the dural attachment), grade III (total removal without coagulation or resection of the dural attachment), grade IV (partial removal), & grade V (biopsy only).

Outcome Measures

The primary outcome was the extent of resection, grouped as complete (Simpson grade I-II) or incomplete (Simpson grade III-V). The secondary outcomes included operative time, loss of intraoperative blood, need for transfusion, and postoperative complications (neurological deficits, hemorrhage, seizures, infection, and mortality) within 30 days of surgery. The operative time was recorded from the initial skin incision to closure, while intraoperative blood loss was estimated by the anesthesiologist based on the suction canister volume and surgical sponge weights.

Data Collection and Analysis

The data were collected prospectively using a standardized case report form. The data comprised of demographic characteristics, clinical presentation, tumor characteristics, embolization details, surgical parameters, and postoperative outcomes. The data were studied using descriptive statistics, and comparisons between the embolized and non-embolized groups were done by chi-square test for categorical variables and the Mann-Whitney U or Student's t-test for continuous variables, as appropriate. Multivariate logistic regression analysis was performed. A p-value <0.05 was considered

statistically significant, and all analyses were performed using SPSS version 26.0 (IBM Corp., Armonk, NY, USA).

RESULTS

Demographic & Clinical Characteristics

The study included 15 patients with intracranial meningiomas, of which 8 underwent preoperative embolization (embolization group), and 7 did not (non-embolization group). Detailed demographic information is provided in Table 1.

Table 1: Patient Demographics and Clinical Features

Characteristic	Embolization Grp (n=8)	Non-Embolization Grp (n=7)	P value
Age (mean ± SD)	53.4 ± 11.2	55.1 ± 12.6	0.785
Gender (Female) (n, %)	5 (62.5%)	4 (57.1%)	0.819
KPS score (median [IQR])	80 [70-90]	80 [70-90]	0.902
Headache (n, %)	5 (62.5%)	4 (57.1%)	0.819
Seizures (n, %)	2 (25.0%)	1 (14.3%)	0.590
Focal neurological deficit (n, %)	3 (37.5%)	2 (28.6%)	0.704
Hypertension (n, %)	3 (37.5%)	3 (42.9%)	0.819
Diabetes mellitus (n, %)	1 (12.5%)	2 (28.6%)	0.427

Tumor Characteristics

The mean tumor size was similar in both Groups- with 4.6 ± 1.3 cm in the embolization Group and 4.4 ± 1.5 cm in the non-embolization Group (p=0.784). The most common tumor location was convexity (p=0.819), followed by skull base (p=0.704) and parasagittal/falcine (p=0.872). High vascularity was observed in 75.0% (p=0.872) and peritumoral edema was present in 62.5% of tumors in the embolization Group (p=0.819).

Among the 8 patients who underwent preoperative embolization, 62.5% (5/8) were embolized using polyvinyl alcohol particles, while 37.5% (3/8) were embolized using tris-acryl gelatin microspheres. Complete embolization was achieved in 75.0% (6/8) of cases, though partial embolization was observed in 25.0% (2/8). No instances of incomplete embolization were reported. Complications related to embolization occurred in 12.5% (1/8) of patients. The average time interval between embolization and surgery was 36.4 ± 8.2 hours. (Figure 1)

Embolization Details

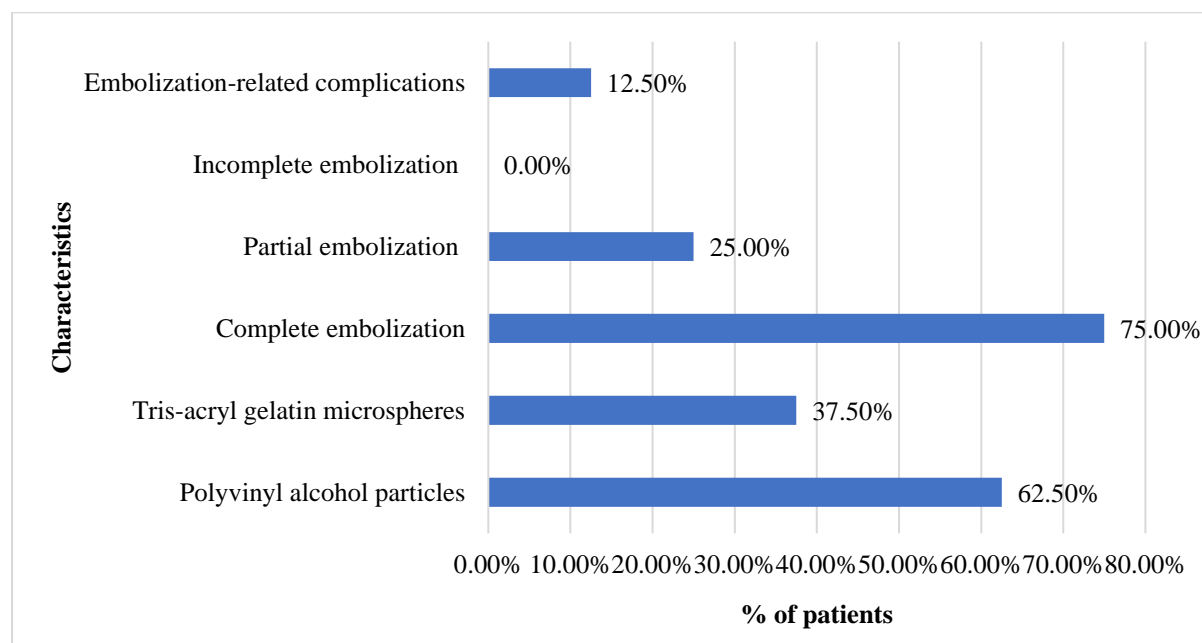


Figure 1: Characteristics of Preoperative Embolization in Patients with Large Meningiomas

Surgical Parameters

Complete resection (Simpson grade I-II) was accomplished in 87.5% (7/8) of patients in the embolization grp, Vs 57.1% (4/7) in the non-embolization grp (p= 0.176). Average operative time reduced in the embolization grp (248.8 ± 68.4 minutes) Vs the non-embolization grp (285.7 ± 75.2 minutes) (p=0.334). Similarly, the mean intraoperative blood loss was reduced in the embolization grp (425.0 ± 180.6 mL) compared to the non-embolization grp (578.6 ± 214.3 mL), but this was not statistically significant (p=0.152). The need for transfusions was 25.0% (2/8) in the

embolization grp, Vs 57.1% (4/7) in the non-embolization grp (p=0.201).

Postoperative Complications

The overall complication rate was 25.0% (2/8). Neurological deficits were observed in 12.5% (1/8) of patients, while no cases of hemorrhage were reported (0.0%). Seizures occurred in 12.5% (1/8) of the cases. Importantly, there were no incidences of infection or mortality reported in the study population. Detailed postoperative outcomes are summarized in Table 2.

Table 2: Postoperative Complications

Complication	Embolization Grp (n=8)	Non-Embolization Grp (n=7)	P value
Neurological deficits (n, %)	1 (12.5%)	2 (28.6%)	0.427
Hemorrhage (n, %)	0 (0.0%)	1 (14.3%)	0.269
Seizures (n, %)	1 (12.5%)	1 (14.3%)	0.916
Infection (n, %)	0 (0.0%)	0 (0.0%)	-
Mortality (n, %)	0 (0.0%)	0 (0.0%)	-
Overall complication rate (n, %)	2 (25.0%)	3 (42.9%)	0.457

Outcomes of Large Meningiomas with Preoperative DSA

In patients who underwent preoperative DSA, the outcomes were generally favorable. The rate of complete resection (Simpson grade I-II) was 87.5%, with a p-value of 0.176. The mean operative time for these cases was 248.8 ± 68.4 minutes (p=0.334). Intraoperative blood loss averaged 425.0 ± 180.6 mL

(p=0.152), and the transfusion requirement was 25.0% (p=0.201). The postoperative complication rate was 25.0% (p=0.457). Although these differences were not statistically significant, the results suggest that preoperative DSA may contribute to achieving complete resection, reducing operative time and intraoperative blood loss, and minimizing postoperative complications.(Table 3)

Table 3: Comparison of Outcomes: Embolized Vs Non-Embolized Groups

Outcome	Embolization Grp (n=8)	Non-Embolization Grp (n=7)	P value
Complete resection (n, %)	7 (87.5%)	4 (57.1%)	0.176
Operative time (mean ± SD) (minutes)	248.8 ± 68.4	285.7 ± 75.2	0.334
Intraoperative blood loss (mean ± SD) (mL)	425.0 ± 180.6	578.6 ± 214.3	0.152
Transfusion requirement (n, %)	2 (25.0%)	4 (57.1%)	0.201
Postoperative complications (n, %)	2 (25.0%)	3 (42.9%)	0.457

Factors Related to Extent of Resection and Complications

A multivariate logistic regression analysis was conducted to identify factors associated with the extent of resection and postoperative complications in patients with large meningiomas managed with preoperative DSA. The analysis revealed that age (OR: 0.96, 95% CI: 0.87-1.06, p=0.428), tumor size (OR: 0.68, 95% CI: 0.28-1.67, p=0.402), and

embolization status (OR: 5.25, 95% CI: 0.53-51.97, p=0.157) were not significantly associated with the extent of resection. Similarly, factors such as age (OR: 1.03, 95% CI: 0.93-1.14, p=0.589), skull base location (OR: 2.80, 95% CI: 0.31-25.18, p=0.357), and the extent of resection (OR: 0.32, 95% CI: 0.03-3.09, p=0.325) were not significantly linked to postoperative complications.

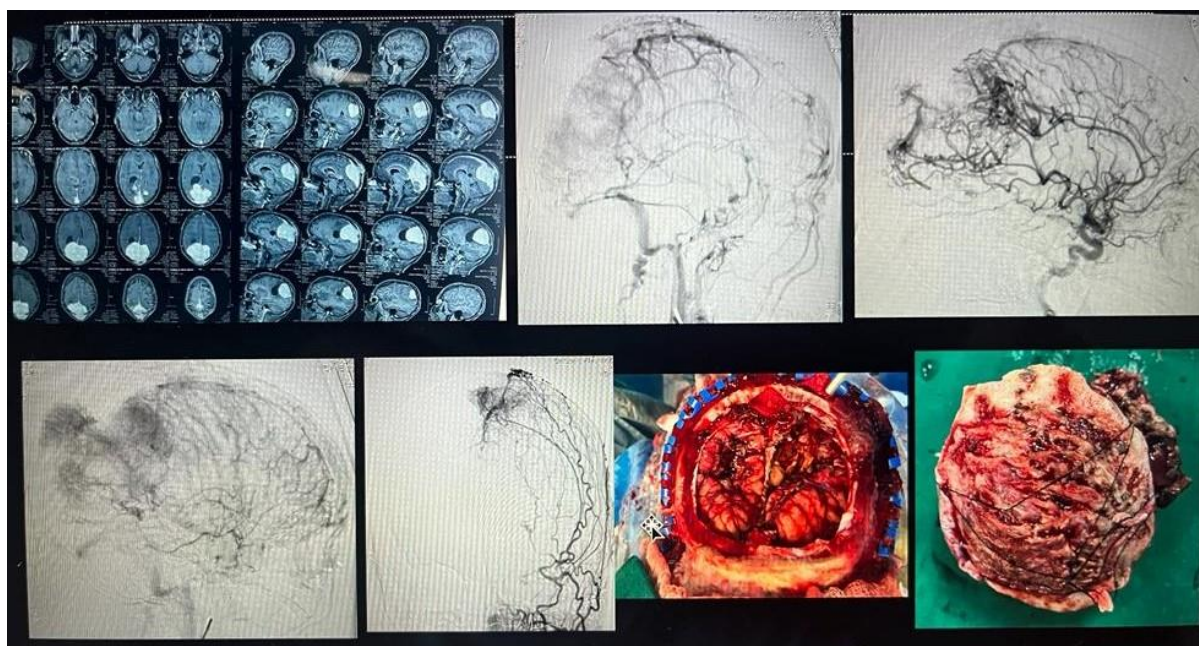


Fig 2: Image palette showing pre-operative MRI, pre-operative DSA, intra-operative and postoperative specimen of B/L parieto-occipital meningioma excised after preoperative embolization

DISCUSSION

This prospective study explored the surgical outcomes of intracranial meningiomas managed with preoperative Digital Subtraction Angiography (DSA). The findings suggest that preoperative DSA may be associated with favourable outcomes, including a higher rate of complete resection, shorter surgery duration, reduced intraoperative blood loss, and fewer transfusions, although these differences were not statistically significant.

Specifically, the rate of complete resection (Simpson grade I-II) in patients who underwent preoperative DSA was 87.5% ($p=0.176$), highlighting the potential of DSA to aid in achieving thorough tumour removal. This result aligns with previous studies, such as Raper et al., which reported a higher resection rate in similar settings [11]. However, some meta-analyses, like that by Ilyas et al., found no significant difference in resection rates when comparing different preoperative strategies (OR: 1.24, 95% CI: 0.75-2.06, $p=0.41$). [12].

The mean operative time was reduced to 248.8 ± 68.4 minutes ($p=0.334$) in cases where DSA was utilized, which is consistent with findings from studies such as those by Shah et al., reported a mean operative time of 298 ± 102 minutes in the embolization Grp and 356 ± 138 minutes in the non-embolization Grp ($p=0.02$) [13].

The mean intraoperative blood loss was lower in the embolization grp (425.0 ± 180.6 mL) compared to the non-embolization grp (578.6 ± 214.3 mL), though this difference was not statistically significant ($p=0.152$). This observation was in line with a retrospective study, which reported a mean intraoperative blood loss of 408 ± 325 mL in the

embolization Grp and 656 ± 421 mL in the non-embolization Grp ($p=0.001$) [14].

The transfusion requirement was reduced in the embolization Grp (25.0%) Vs the non-embolization Grp (57.1%), but this difference was not statistically significance ($p=0.201$). The finding aligns with a retrospective analysis, which reported a transfusion requirement of 18.2% in the embolization Grp and 33.3% in the non-embolization Grp ($p=0.04$) [15]. Oka et al. demonstrated that patients with skull base meningiomas who underwent embolization of tumors smaller than 6 cm had significantly less blood loss. In tumors larger than 6 cm, there was no significant difference in blood loss between patients who had undergone embolization and those who had not, perhaps because larger meningiomas have collateral blood vessels in which embolization is unviable.[16]

Postoperative complications occurred in 25.0% of cases ($p=0.457$), a rate comparable to those reported in the literature. Meta-analyses, such as that by Galal et al., have similarly found no significant difference in complication rates across various preoperative management strategies (OR: 0.80, 95% CI: 0.58-1.10, $p=0.17$) [17]. However, some studies, like Chen et al., have observed higher complication rates with certain preoperative interventions [18].

Multivariate logistic regression analysis revealed that age, tumor size, and DSA status were not significantly associated with the extent of resection or complications. This contrasts with studies such as Przybylowski et al., which identified tumor size and preoperative intervention as significant predictors of surgical outcomes [19]. Similarly, a retrospective study by Singla et al. analyzed skull base location (OR: 2.84, 95%CI: 1.12-7.17, $p=0.03$) and

incomplete resection (OR:3.47, 95% CI:1.36-8.90, p=0.009) were independent predictors of postoperative complications [20].

The limitations include a modest sample size and no randomization, which could have introduced selection bias. Furthermore, the study was conducted at a single institution, the findings may not be widely applicable.

CONCLUSION

This study highlights the importance of preoperative DSA in the surgical management of large meningiomas. The detailed vascular information provided by DSA can significantly aid in surgical planning, contributing to favorable outcomes. The results indicate that preoperative embolization might be linked to a higher rate of complete tumor resection, reduced operative time, and loss of intraoperative blood, and a lower transfusion requirement. However, these differences did not achieve statistical significance. The embolization group experienced fewer complications than the non-embolization group. Multivariate analysis did not identify any significant factors affecting the extent of resection or complications. Further research is necessary to validate these findings and establish standardized protocols for the use of DSA in meningioma surgery.

REFERENCES

1. Ostrom QT, Cioffi G, Gittleman H, Patil N, Waite K, Kruchko C, et al. CBTRUS Statistical Report: Primary Brain and Other Central Nervous System Tumors Diagnosed in the United States in 2012-2016. *Neuro Oncol*. 2019;21(Suppl 5):v1-v100. doi:10.1093/neuonc/noz150.
2. Wiemels J, Wrensch M, Claus EB. Epidemiology and etiology of meningioma. *J Neurooncol*. 2010;99(3):307-314. doi:10.1007/s11060-010-0386-3.
3. Goldbrunner R, Minniti G, Preusser M, Jenkinson MD, Sallabanda K, Houdart E, et al. EANO guidelines for the diagnosis and treatment of meningiomas. *Lancet Oncol*. 2016;17(9):e383-e391. doi:10.1016/S1470-2045(16)30321-7.
4. Hasseleid BF, Meling TR, Rønning P, Scheie D, Helseth E. Surgery for convexity meningioma: Simpson Grade I resection as the goal: clinical article. *J Neurosurg*. 2012;117(6):999-1006. doi:10.3171/2012.9.JNS12294.
5. Nanda A, Bir SC, Maiti TK, Konar SK, Missios S, Guthikonda B. Relevance of Simpson grading system and recurrence-free survival after surgery for World Health Organization Grade I meningioma. *J Neurosurg*. 2017;126(1):201-211. doi:10.3171/2016.1.JNS151842.
6. Raper DMS, Starke RM, Henderson F Jr, Ding D, Simon S, Evans AJ, et al. Preoperative embolization of intracranial meningiomas: efficacy, technical considerations, and complications. *AJNR Am J Neuroradiol*. 2014;35(9):1798-1804. doi:10.3174/ajnr.A3919.
7. Singla A, Deshaies EM, Melnyk V, Toshkezi G, Swarnkar A, Choi H, et al. Controversies in the role of preoperative embolization in meningioma management. *Neurosurg Focus*. 2013;35(6):E17. doi:10.3171/2013.9.FOCUS13351.
8. Shah AH, Patel N, Raper DMS, Bregy A, Ashour R, Elhammady MS, et al. The role of preoperative embolization for intracranial meningiomas. *J Neurosurg*. 2013;119(2):364-372. doi:10.3171/2013.3.JNS121328.
9. Carli DF, Sluzewski M, Beute GN, van Rooij WJ. Complications of particle embolization of meningiomas: frequency, risk factors, and outcome. *AJNR Am J Neuroradiol*. 2010;31(1):152-154. doi:10.3174/ajnr.A1758.
10. Ilyas A, Chaudhary N, Hussain S, Chaudhary S, Hussain S, Najib S, et al. Preoperative embolization of intracranial meningiomas: a systematic review and meta-analysis. *World Neurosurg*. 2019;128:e59-e68. doi:10.1016/j.wneu.2019.03.262.
11. Raper DMS, Starke RM, Henderson F Jr, et al. Preoperative embolization of intracranial meningiomas: efficacy, technical considerations, and complications. *AJNR Am J Neuroradiol*. 2014;35(9):1798-1804.
12. Ilyas A, Przybylowski C, Chen C-J, et al. Preoperative embolization of intracranial meningiomas: a systematic review and meta-analysis. *J Neurosurg*. 2019;132(6):1942-1949.
13. Shah AH, Patel N, Raper DMS, et al. The role of preoperative embolization for intracranial meningiomas. *J Neurosurg*. 2013;119(2):364-372.
14. Huo L, Zhang J, Wang K, et al. Clinical efficacy of preoperative embolization for intracranial meningioma: a retrospective study. *J Craniofac Surg*. 2019;30(7):2135-2138.
15. Liang Z, Guo S, Zhang J, et al. Preoperative embolization versus direct surgery of meningiomas: a meta-analysis. *World Neurosurg*. 2019;128:62-68.
16. Oka H, Kurata A, Kawano N, Saegusa H, Kobayashi I, Ohmomo T, et al. Preoperative superselective embolization of skull-base meningiomas: indications and limitations. *J Neurooncol* 40:67-71, 1998
16. Galal A, Eltahawy A. Preoperative embolization of intracranial meningiomas: a systematic review and meta-analysis. *J Neurol Surg A Cent Eur Neurosurg*. 2020;81(2):111-117.

17. Chen Y, Li Y, Zhao Q, et al. Preoperative embolization of intracranial meningiomas: a single-center experience. *Clin Neurol Neurosurg.* 2021;200:106365.
18. Przybylowski CJ, Hendricks BK, Frisoli FA, et al. Preoperative embolization versus no embolization for WHO grade I intracranial meningioma: a retrospective matched cohort study. *J Neurosurg.* 2020;134(4):1240-1248.
19. Singla A, Deshaies EM, Melnyk V, et al. Complications of preoperative embolization of meningiomas: a review of literature and a single-center experience. *Neurosurg Rev.* 2021;44(1):301-310.

How to cite this article: Dr. Angirash Bhattacharyya, Dr. Ashim Kumar Boro, Prof (Dr) Mrinal Bhuyan, Dr. Rajesh Kr. Barooah, OUTCOME OF LARGE MENINGIOMA SURGERIES WITH PREOPERATIVE DIGITAL SUBTRACTION ANGIOGRAPHY (DSA): A CLINICAL STUDY, *Asian J. Med. Res. Health Sci.*, 2026; 4 (2):-351-357.

Source of Support: Nil, Conflicts of Interest: None declared.